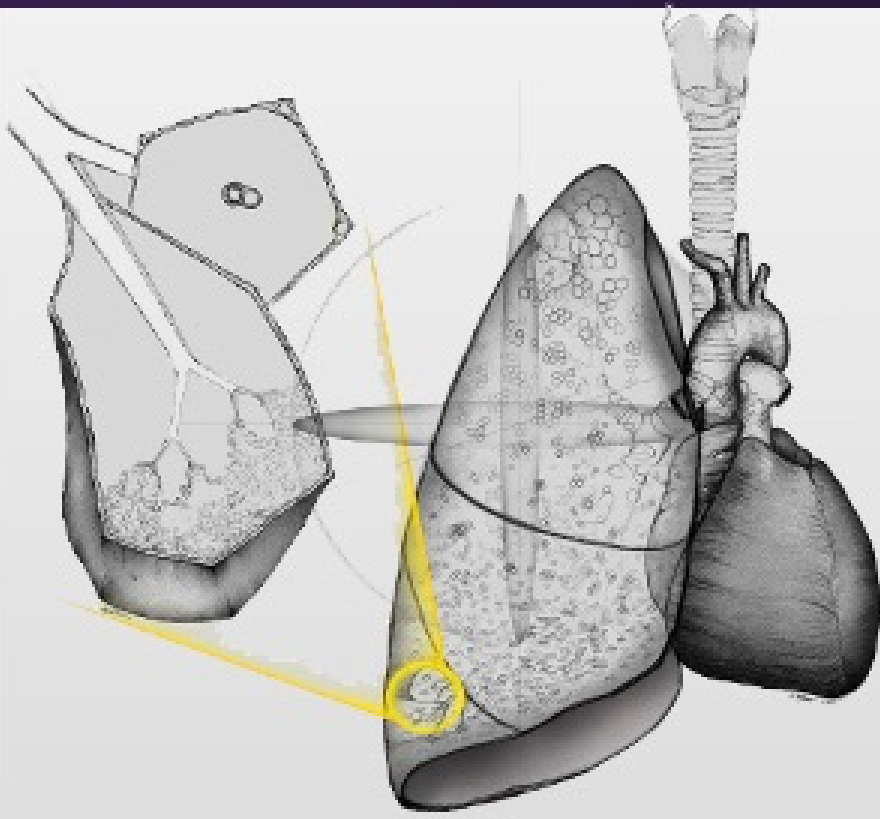

# ATS Pulmonary Fellows Cases 2021

Jeffrey R. Galvin, M.D

Teri J. Franks, M.D.

Nevins Todd, M.D.

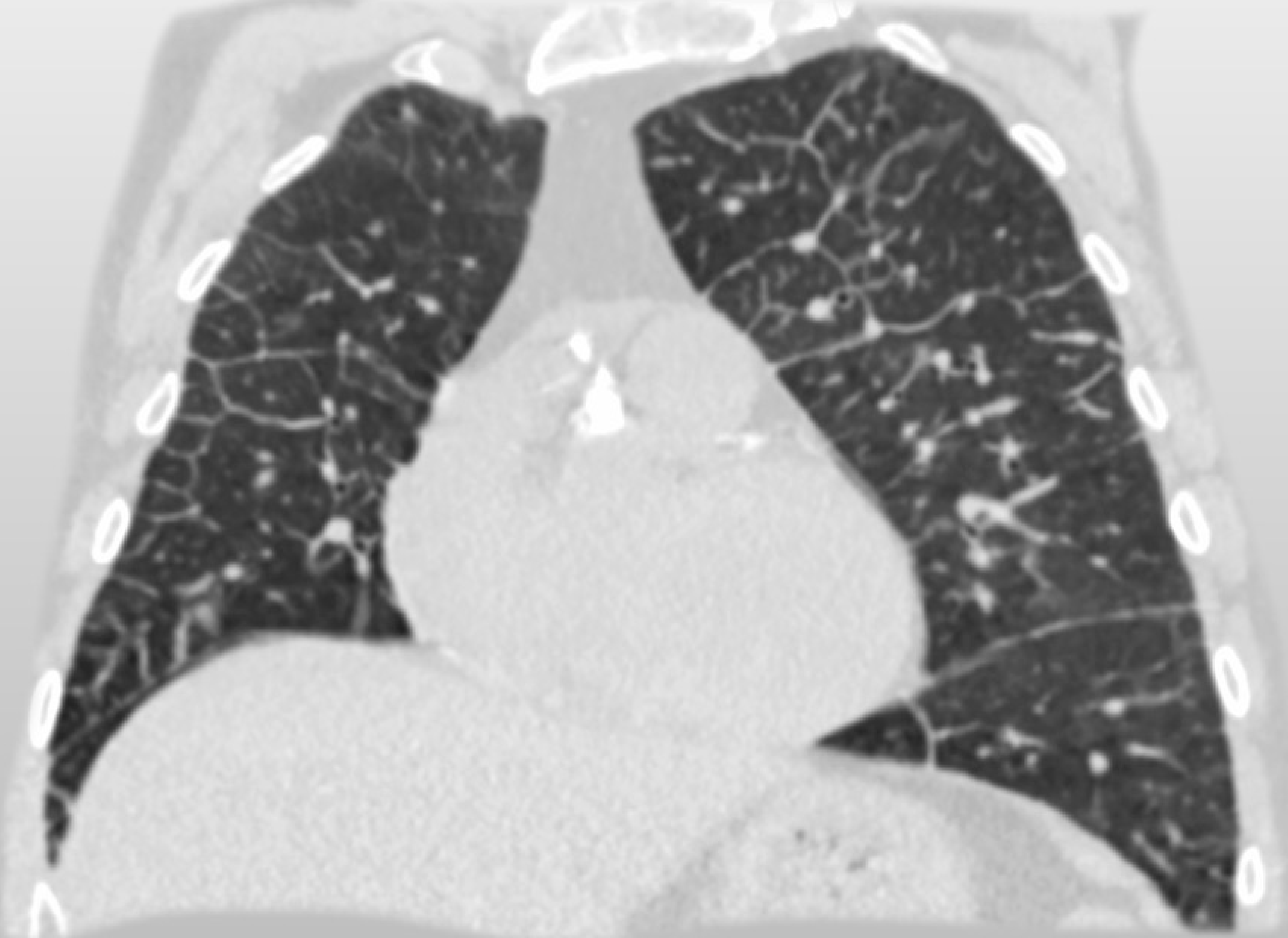


UNIVERSITY of MARYLAND  
MEDICAL CENTER

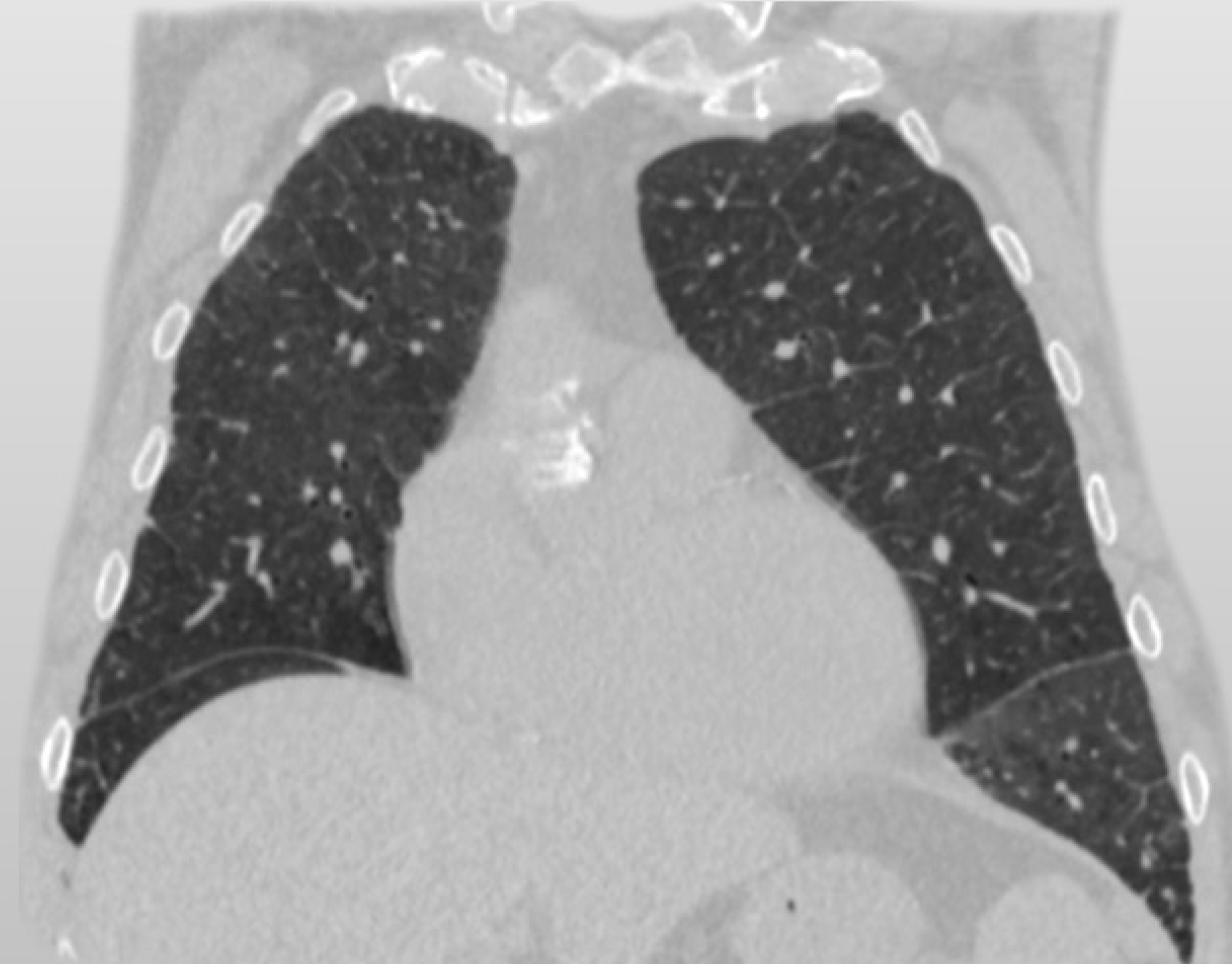
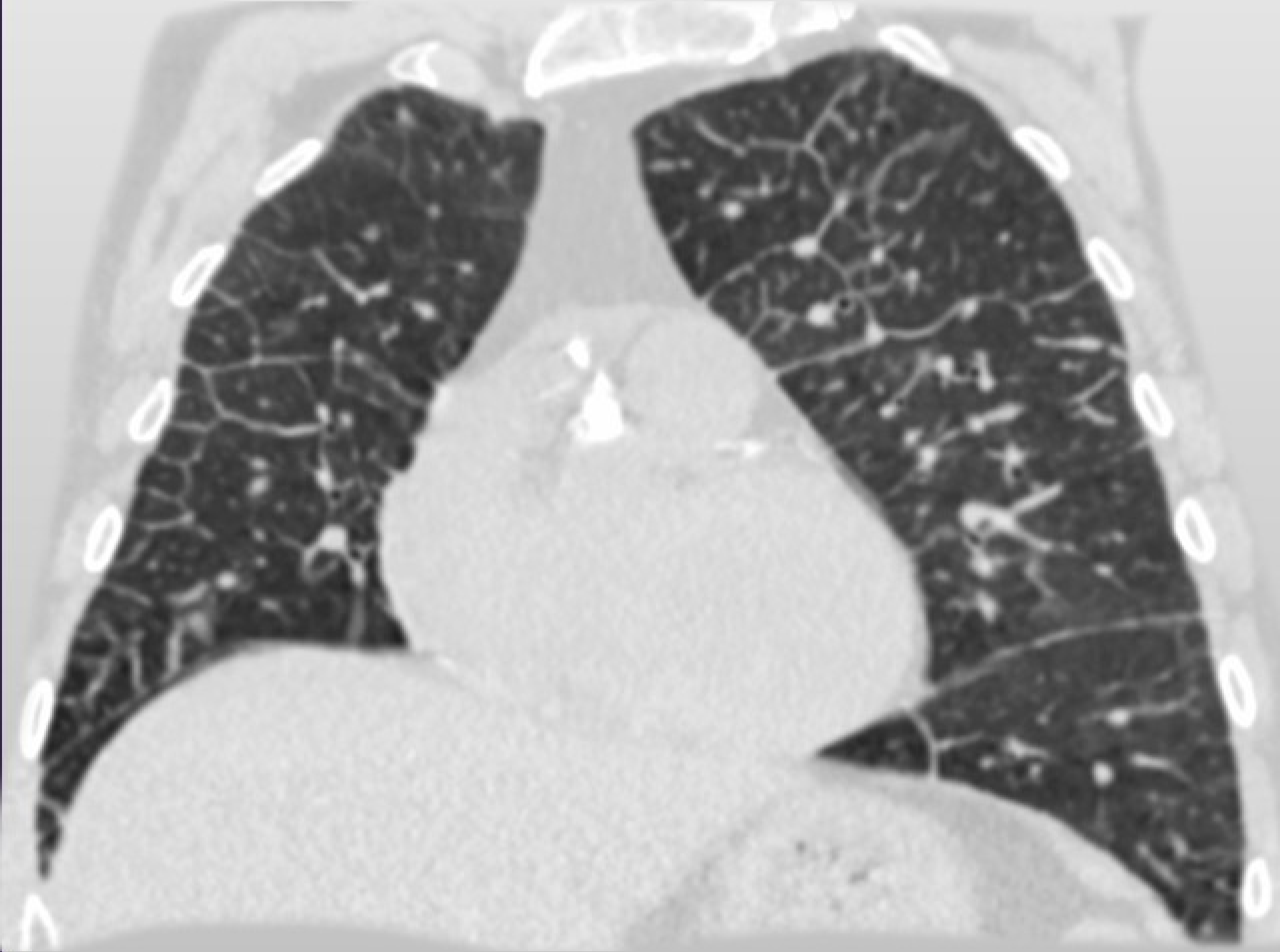# Case 1

- 70-year-old male with progressive dyspnea

# Case 1



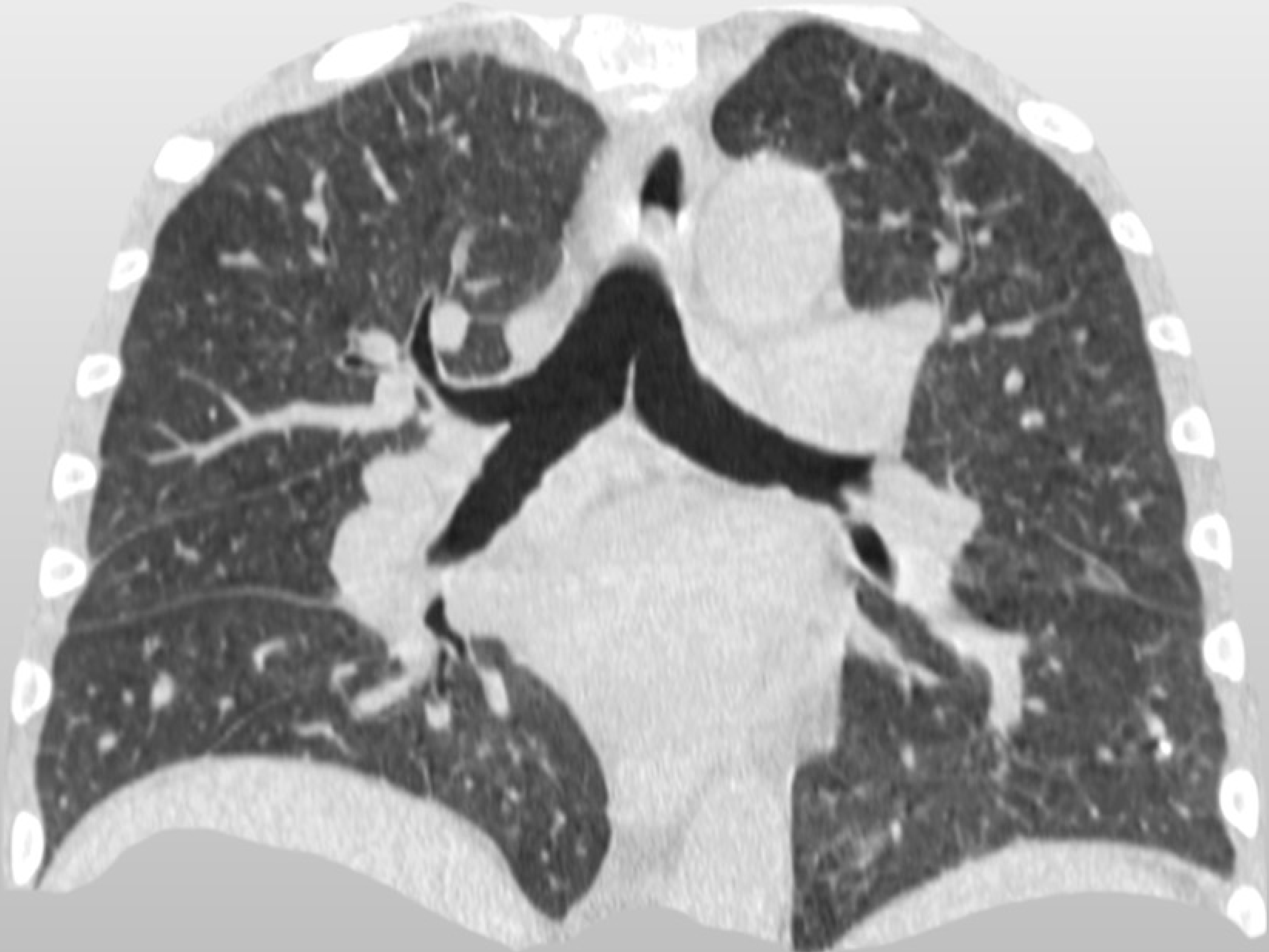
# Lasix



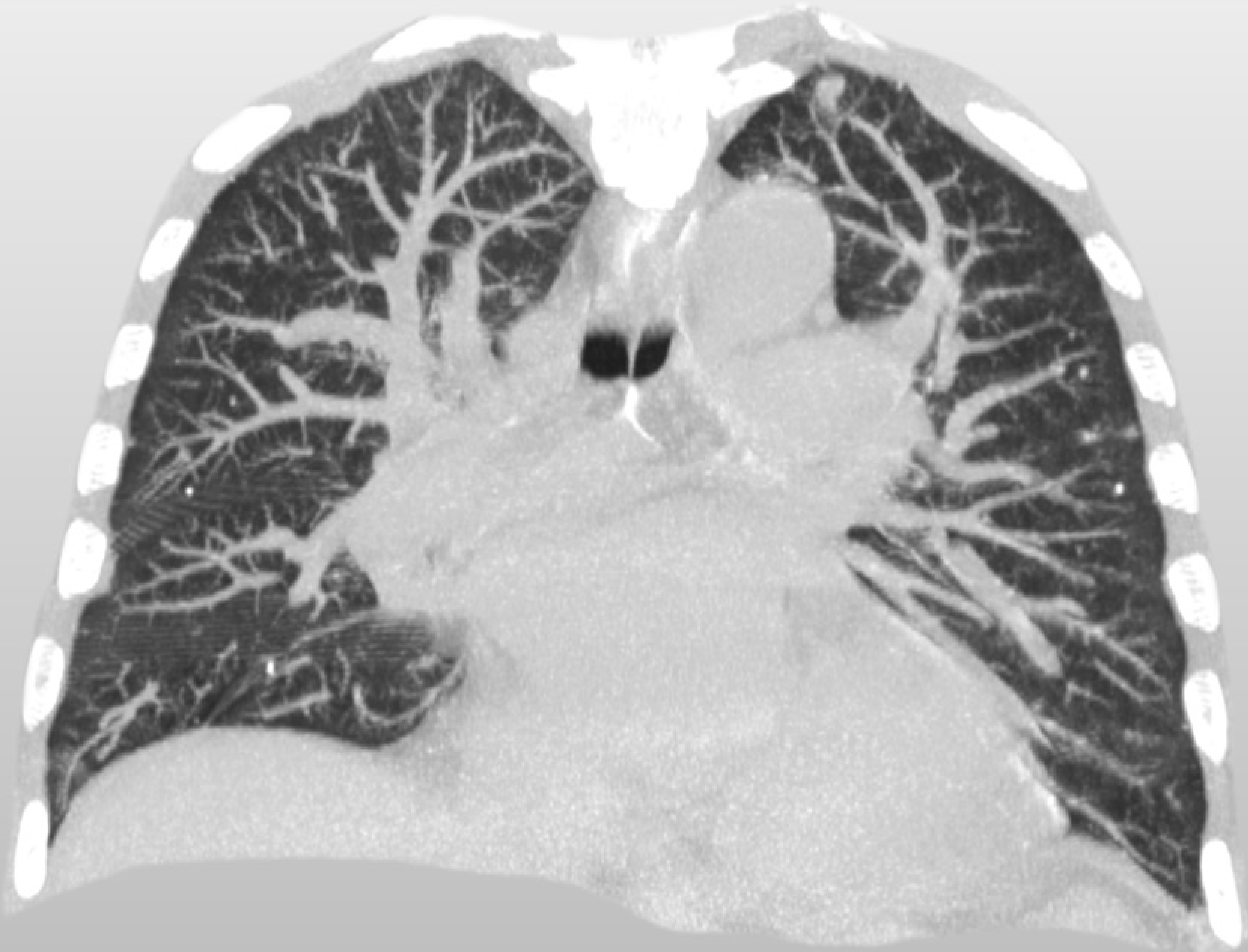
## Case 2

- 68-year-old male with chronic congestive heart failure and suspected interstitial lung disease.

# Case 2



# Case 2

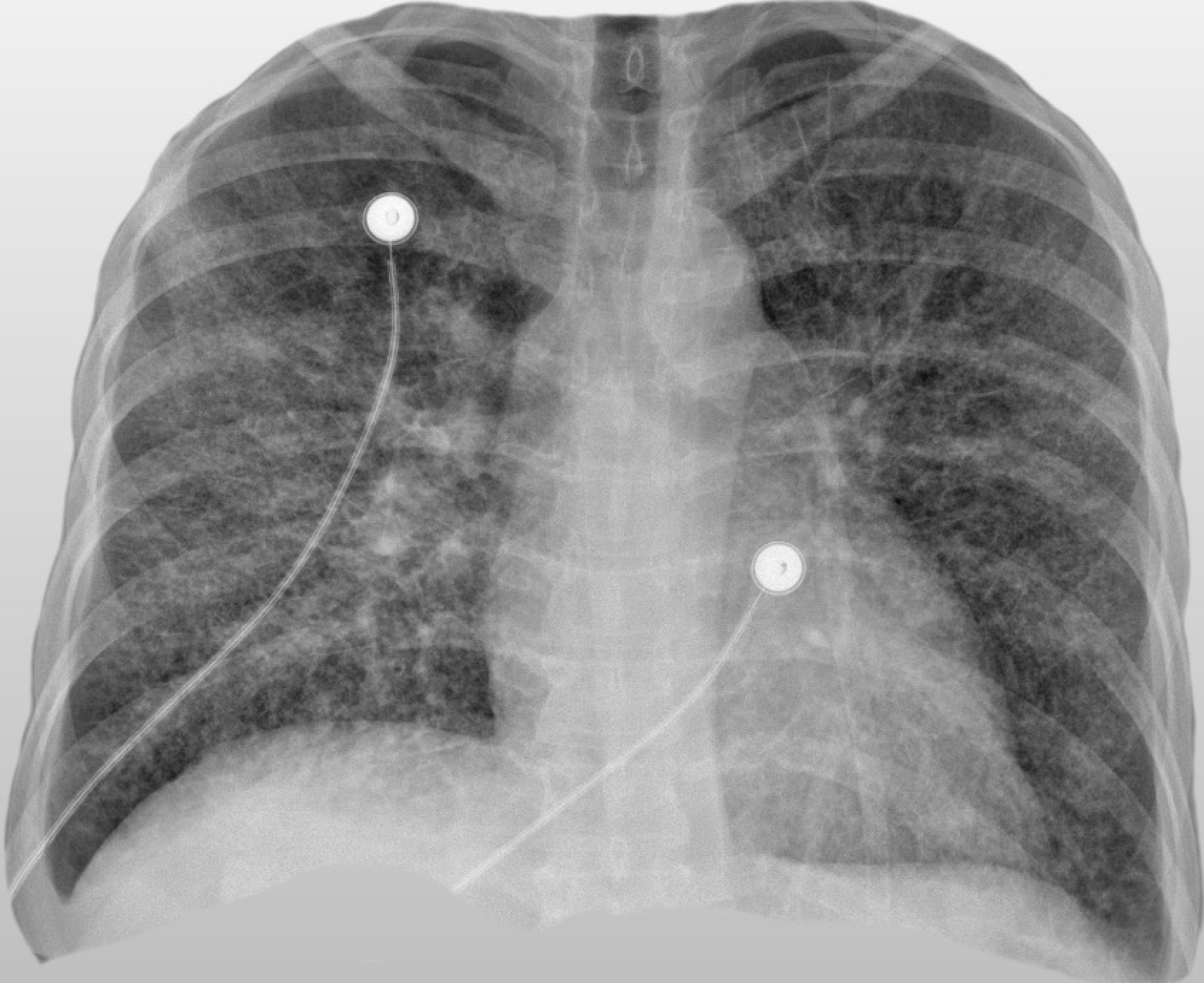


## Case 3

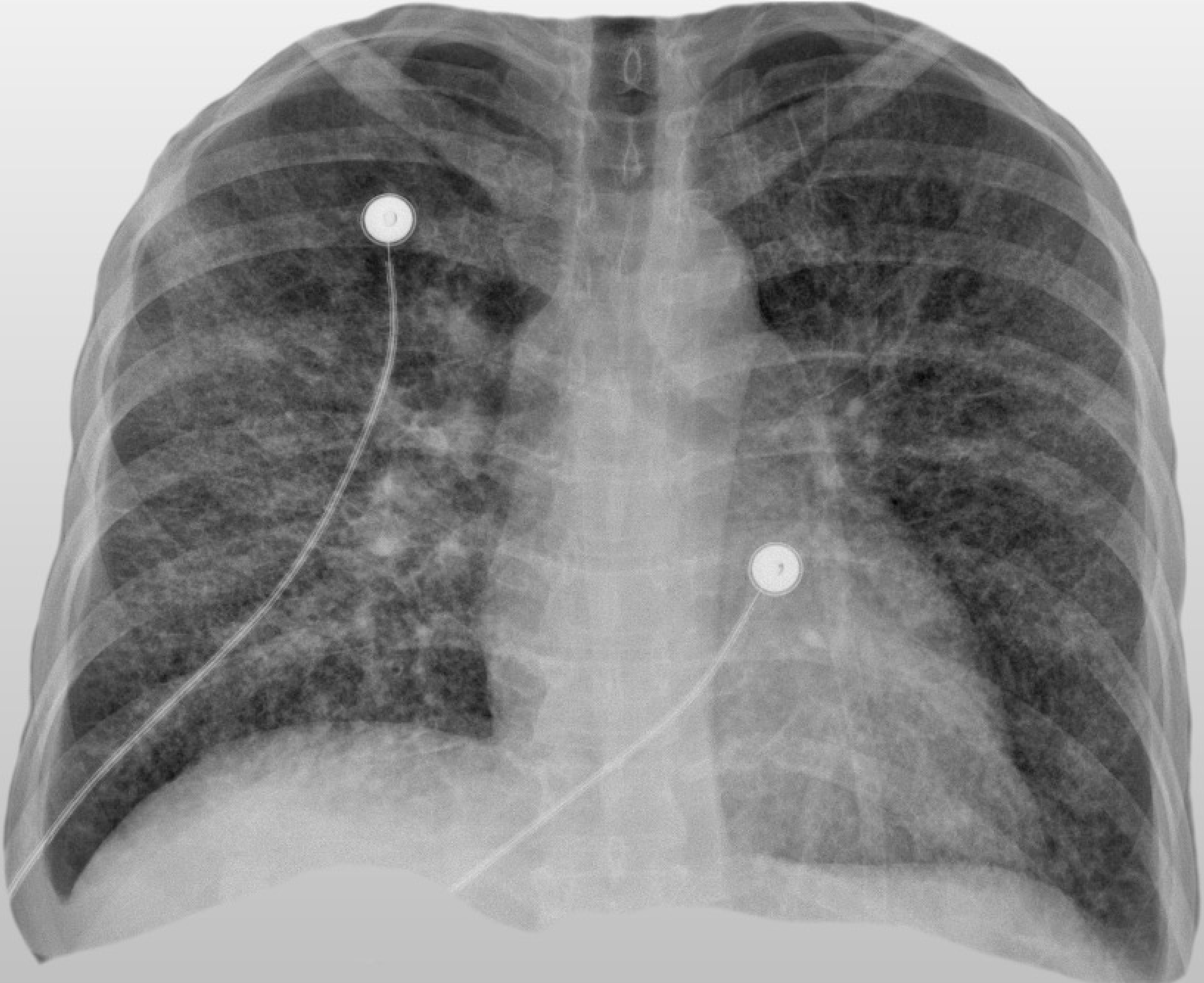
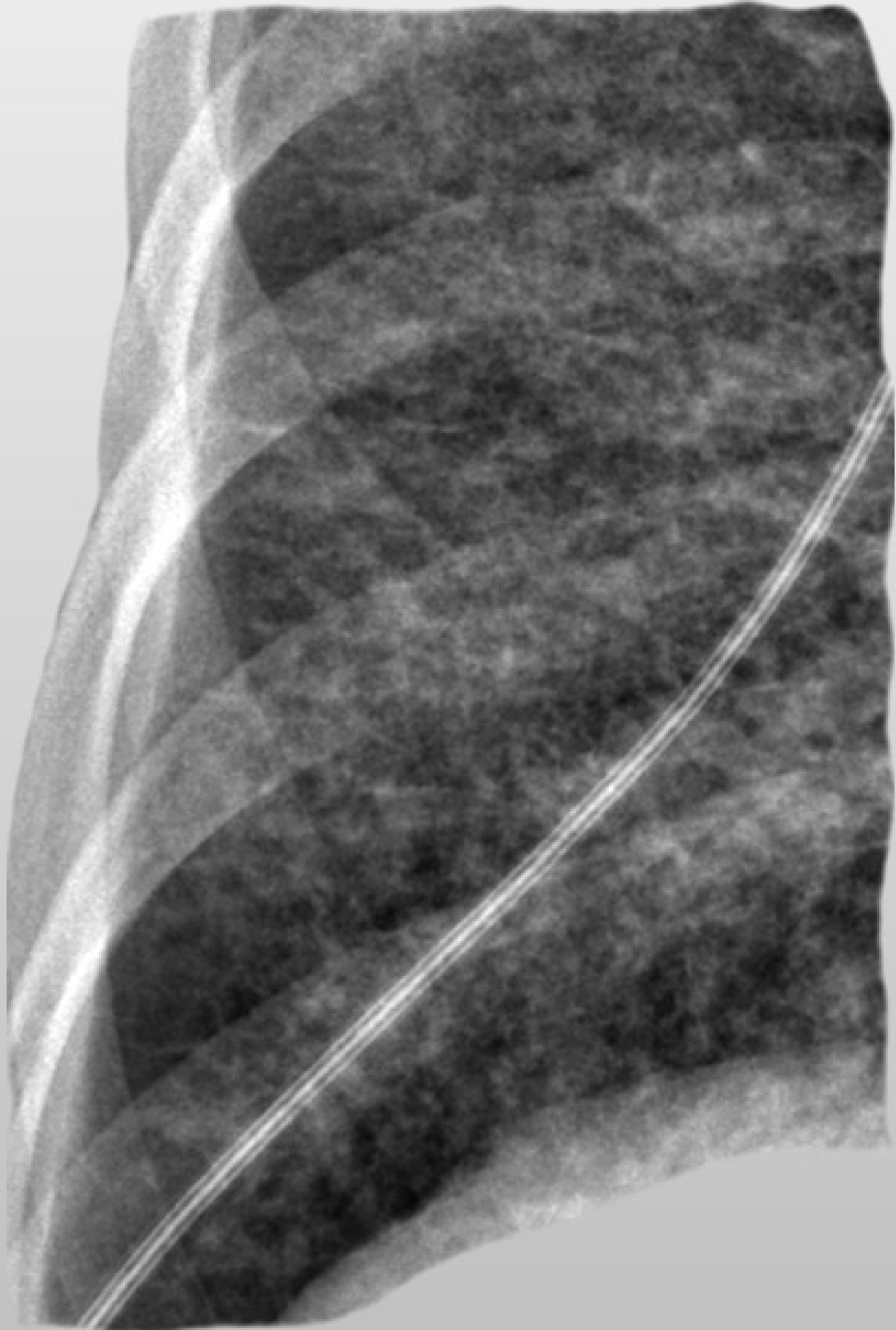- 50-year-old female with gastritis and progressive dyspnea and hypoxia that developed over 6 weeks. Cardiac catheterization demonstrated pulmonary artery hypertension. A pulmonary embolus study was acquired.



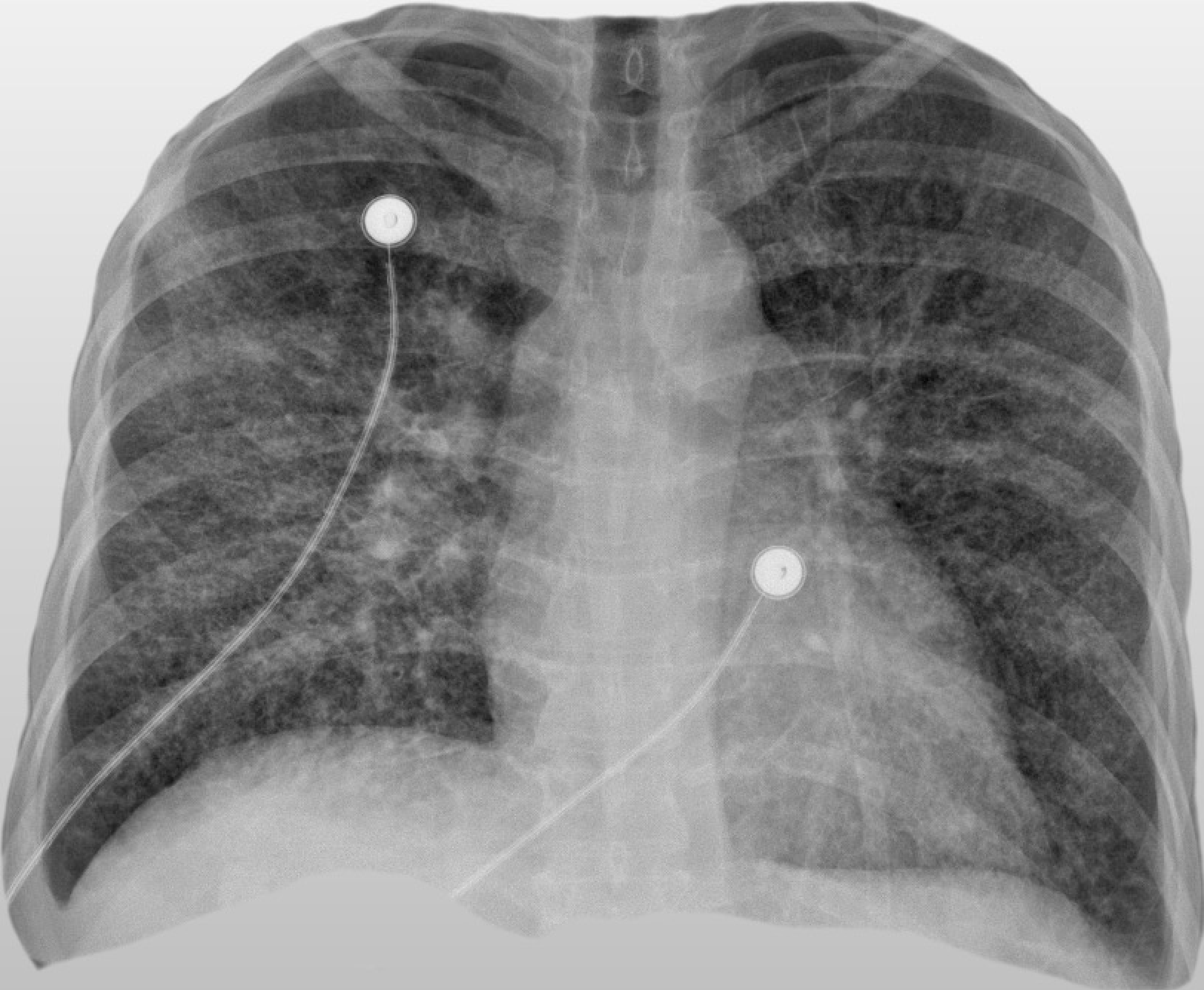
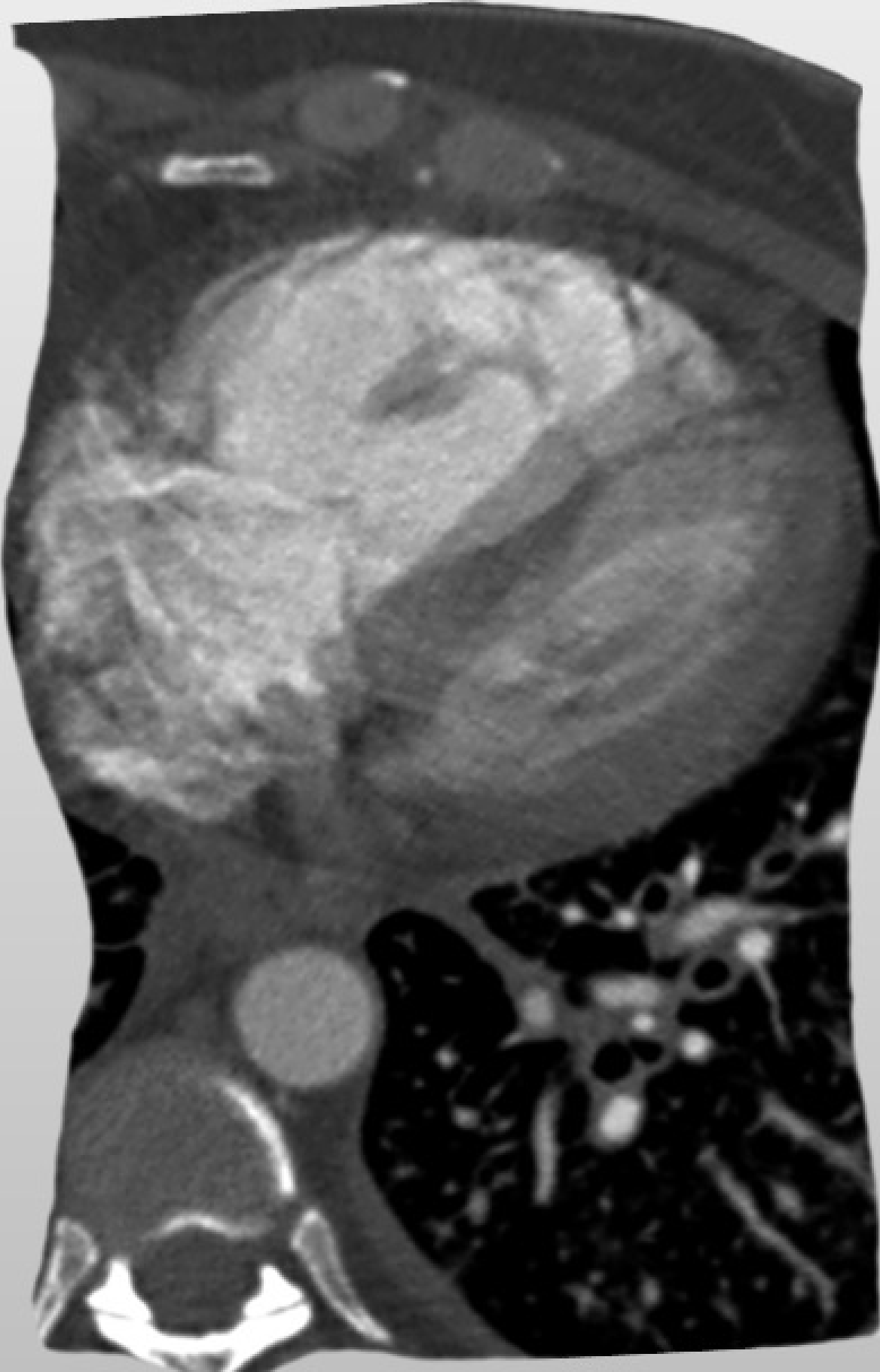
# Case 3



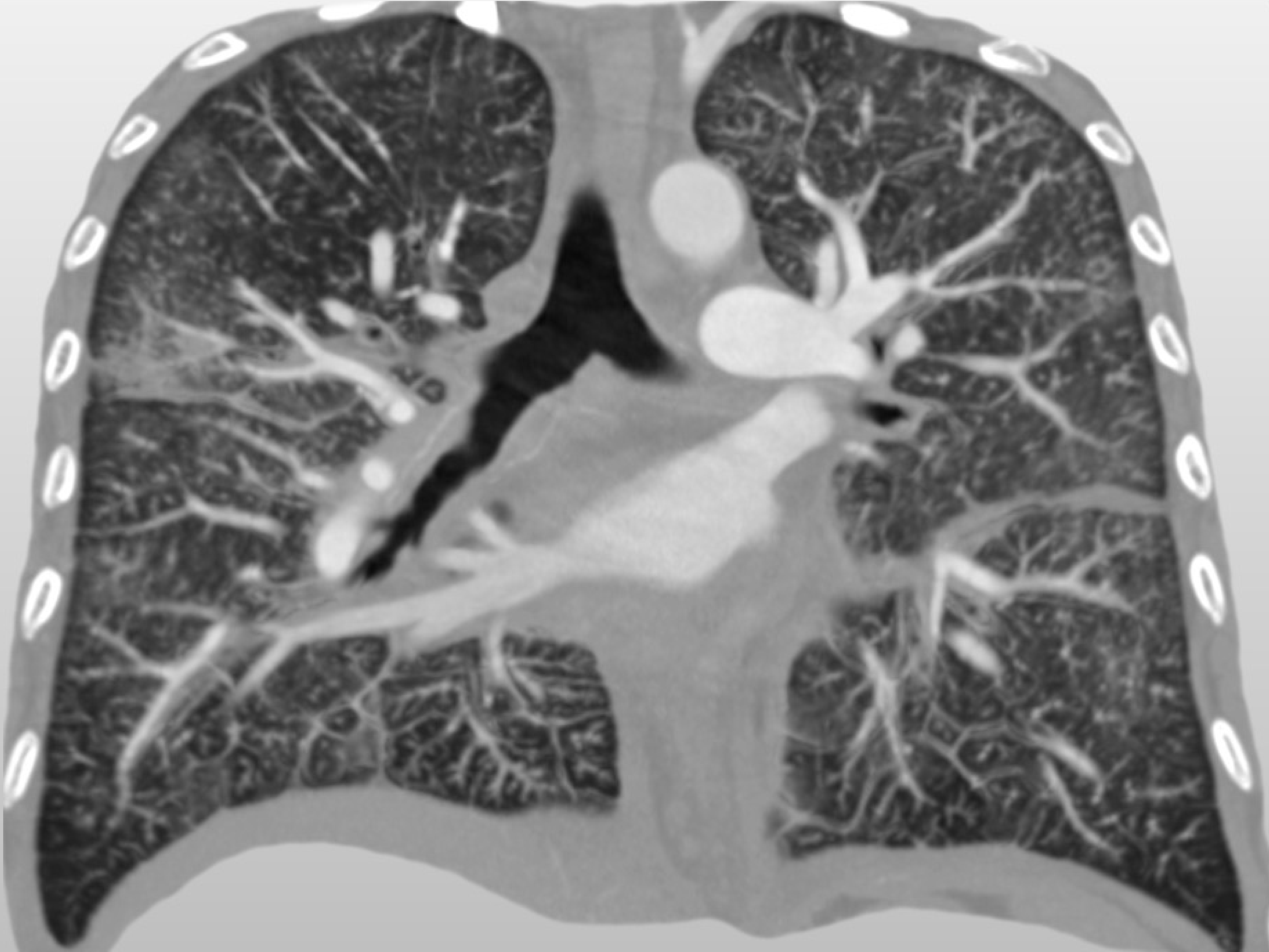**Case 3**



# Case 3



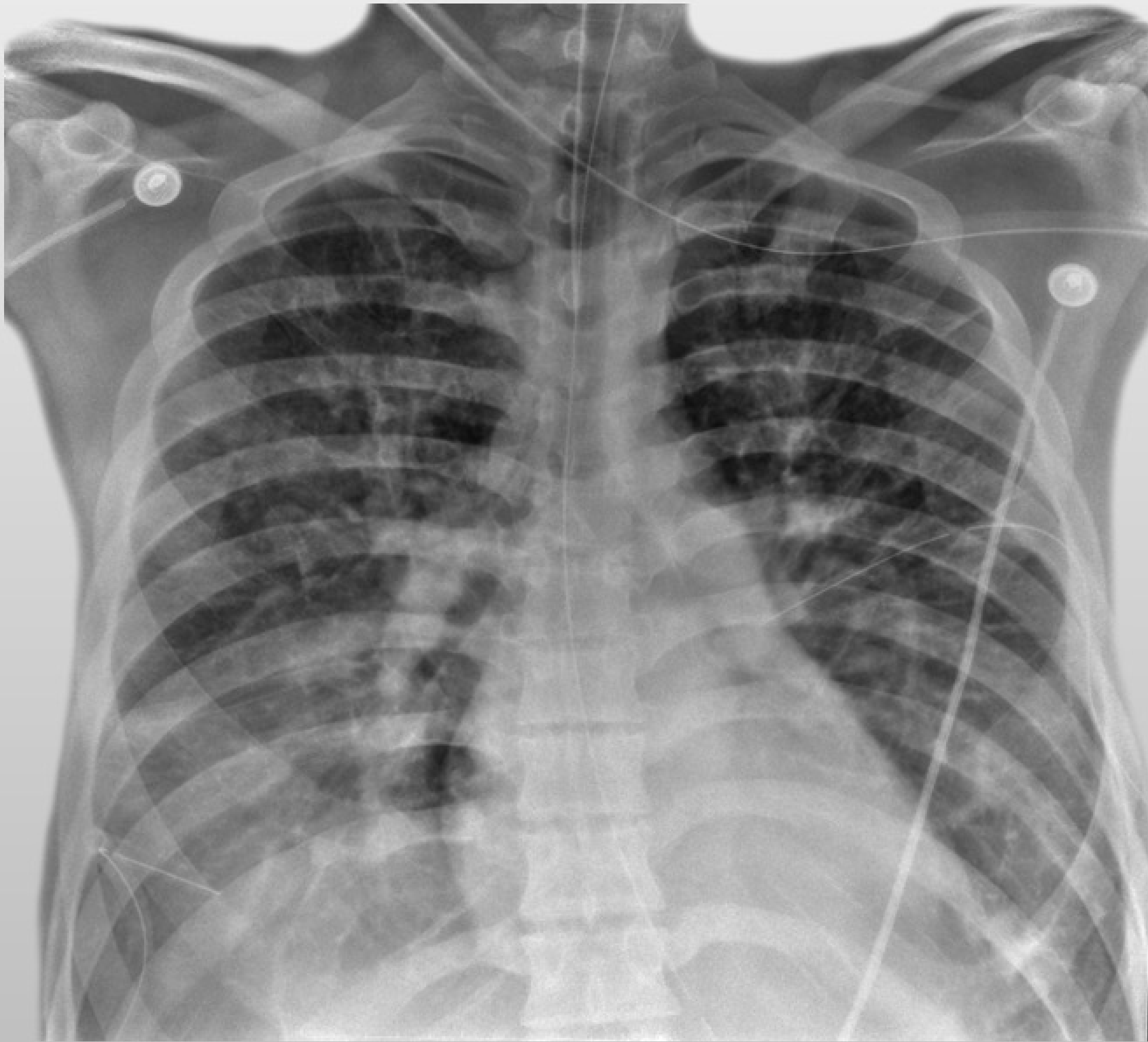
**Case 3**



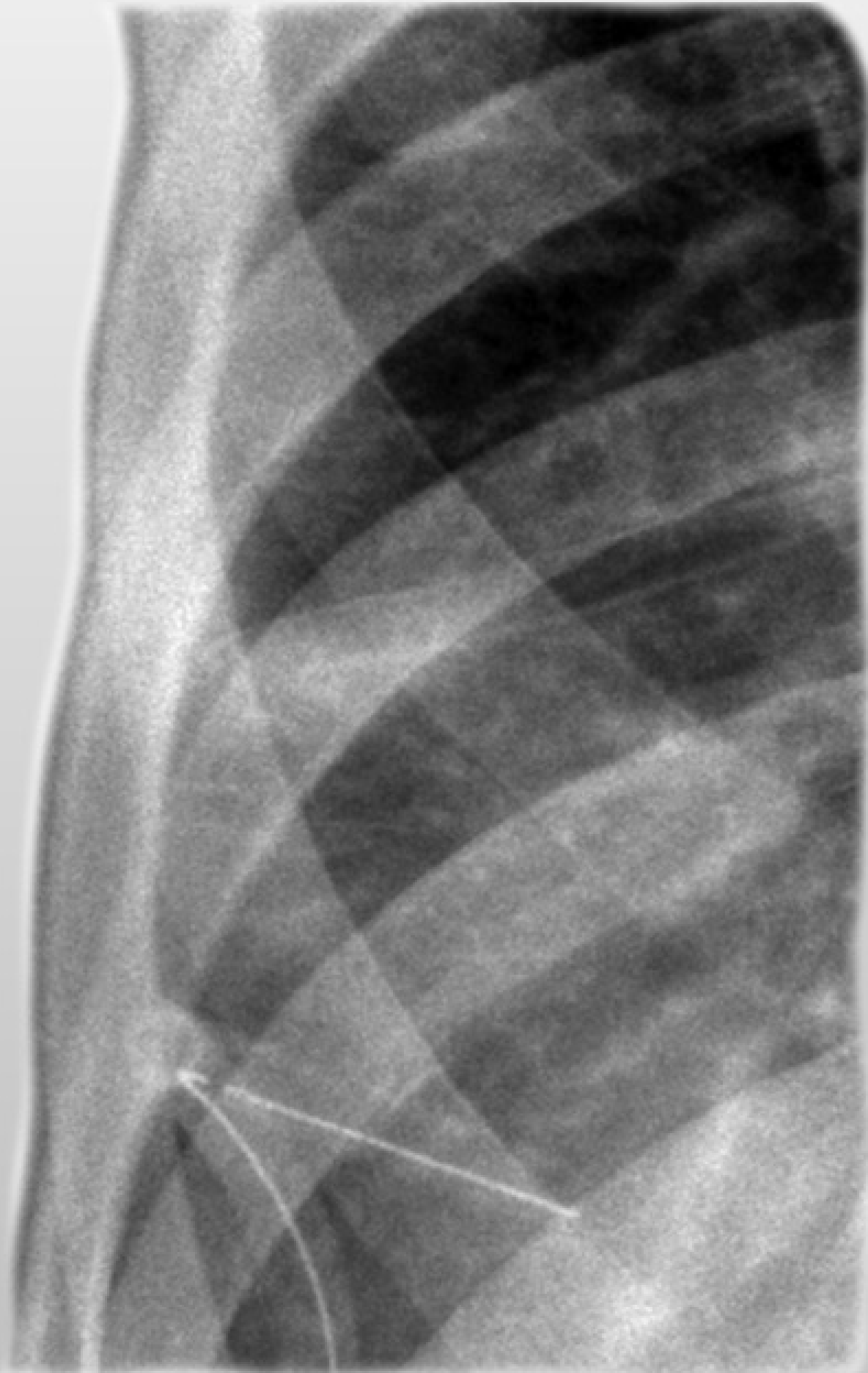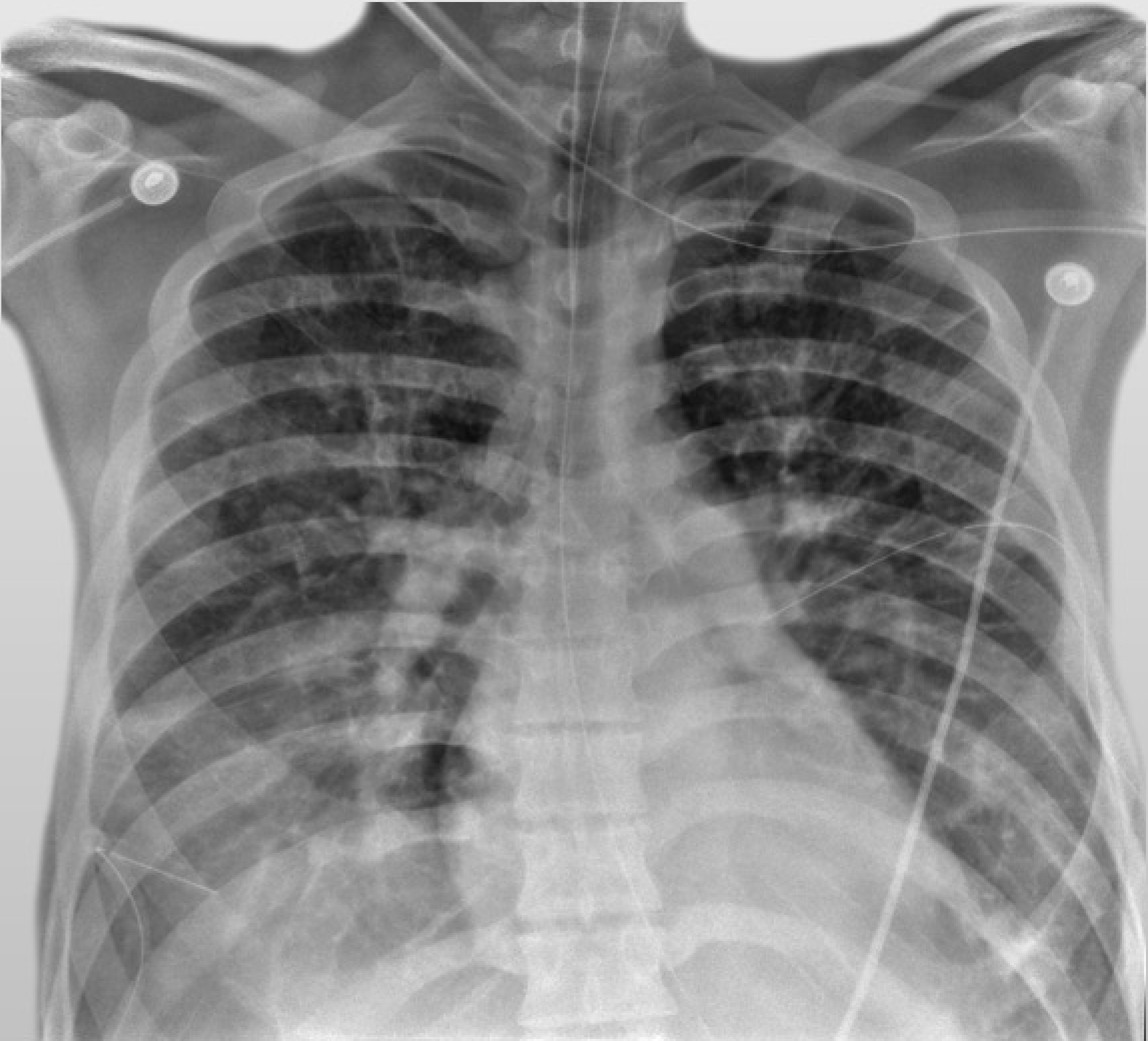
## Case 4

- 23-year-old male, military photographer with rapid onset of dyspnea 10 days after arriving in Iraq. The patient required intubation in the field with transfer to Landstuhl Regional Medical Center in Germany

# Case 4

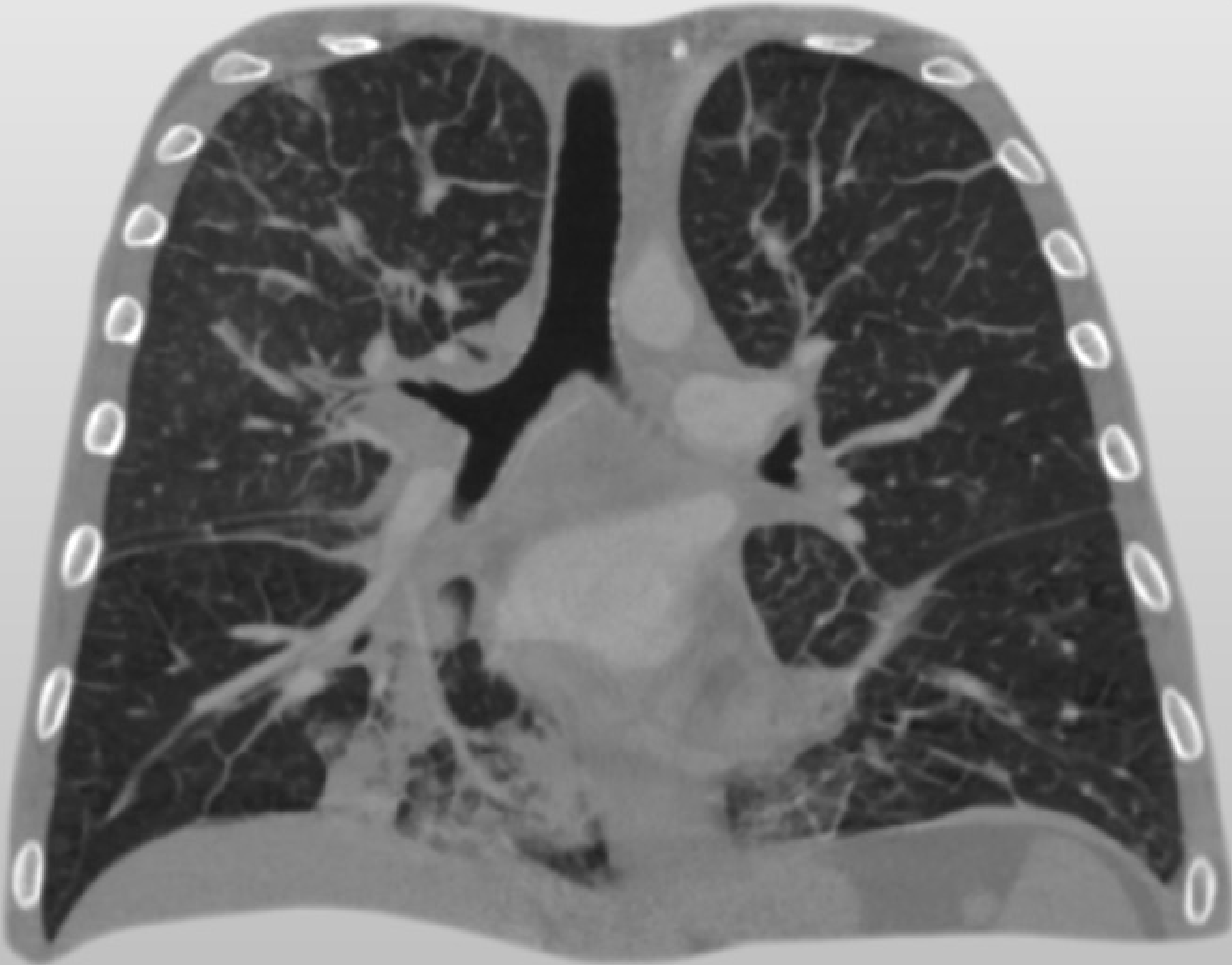
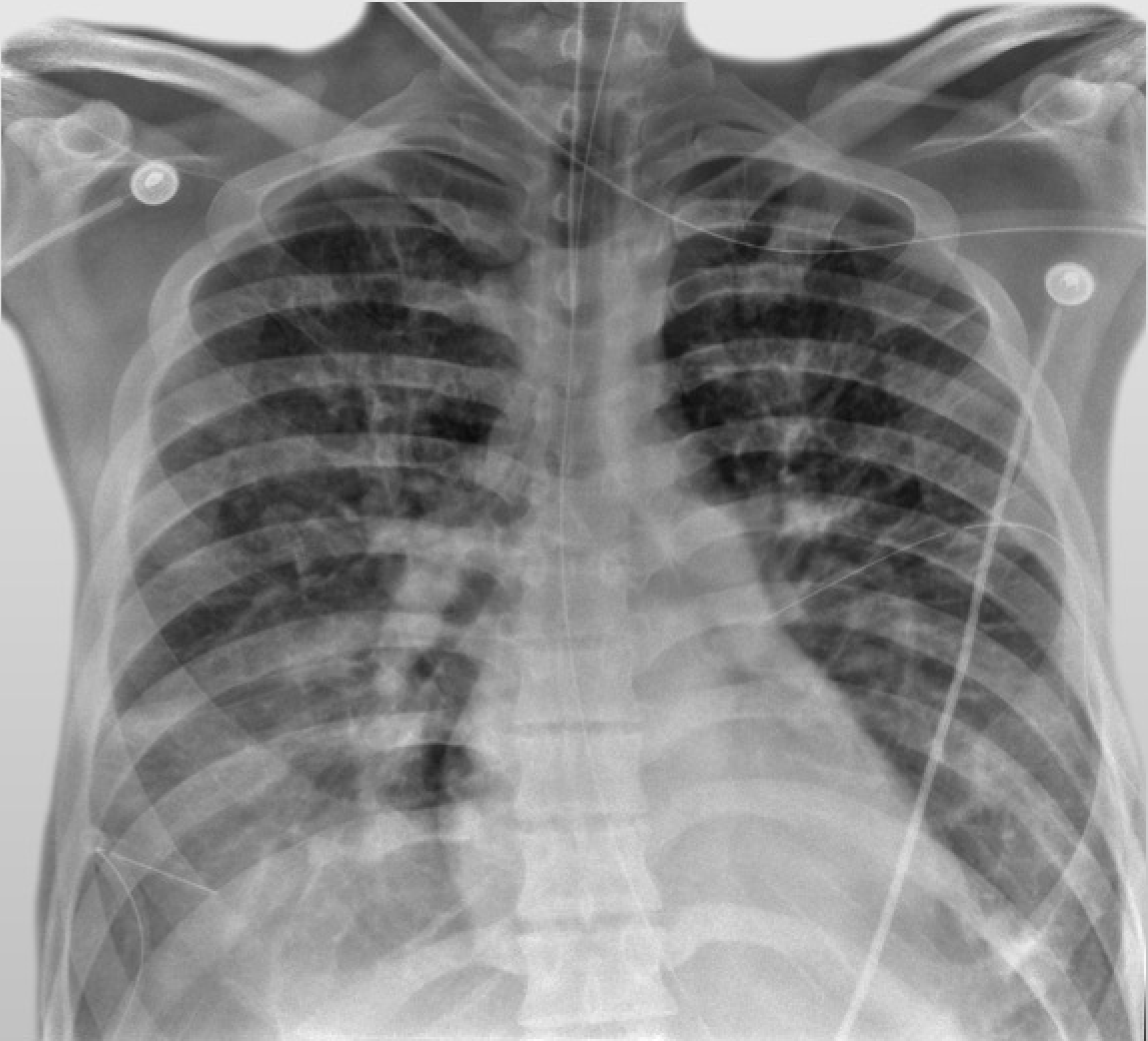


# Case 4



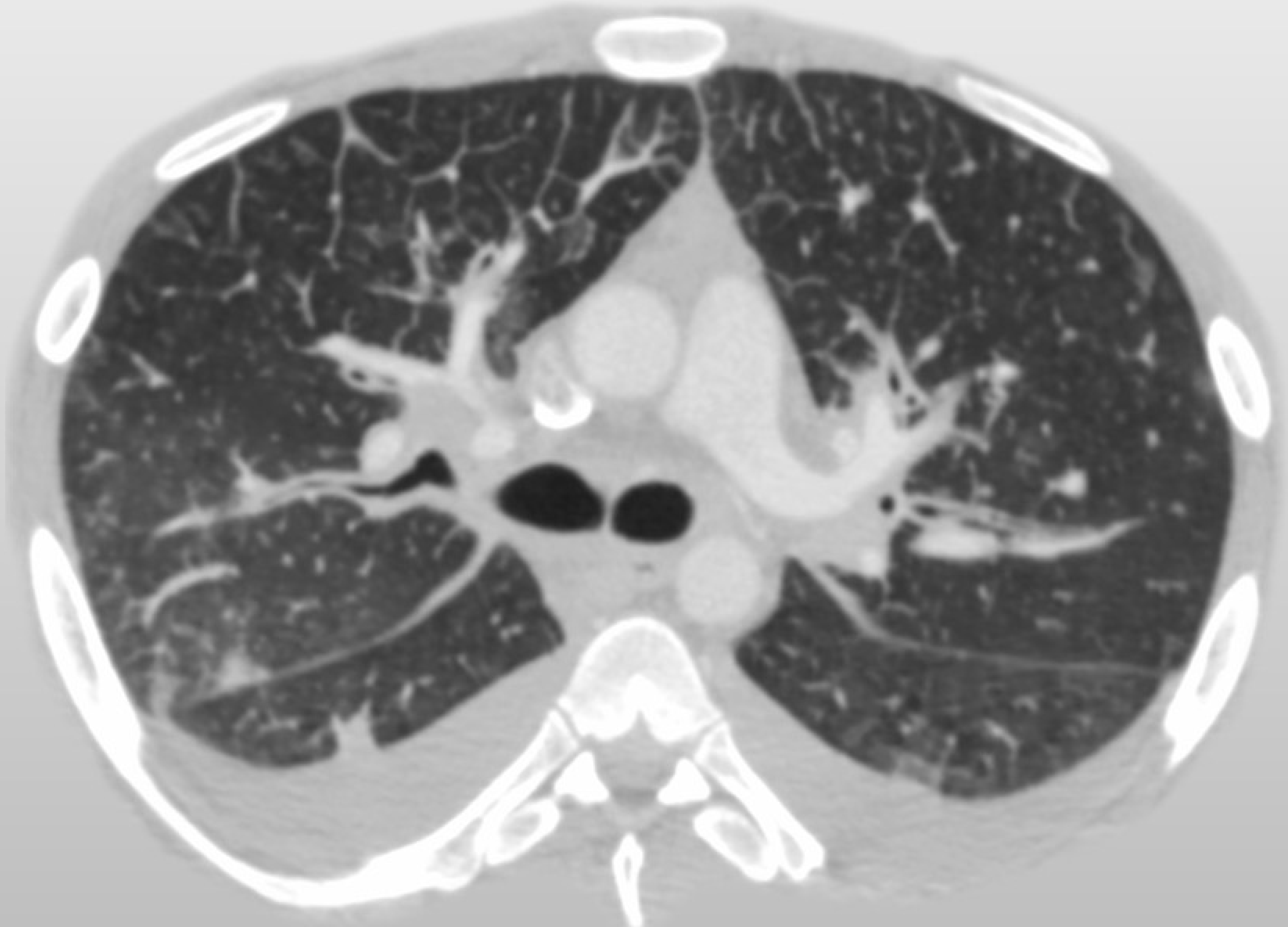

# Case 4





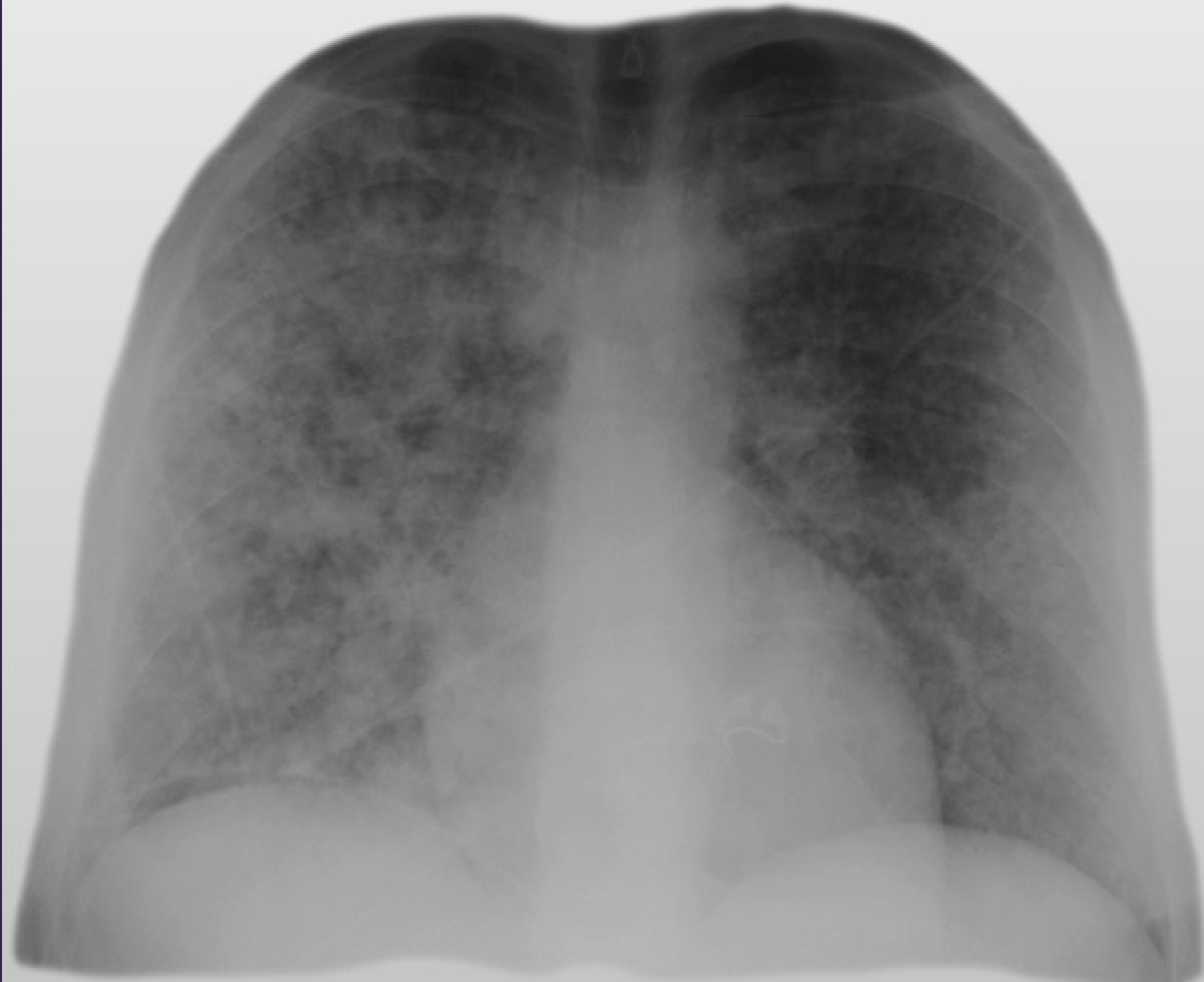
Case 4



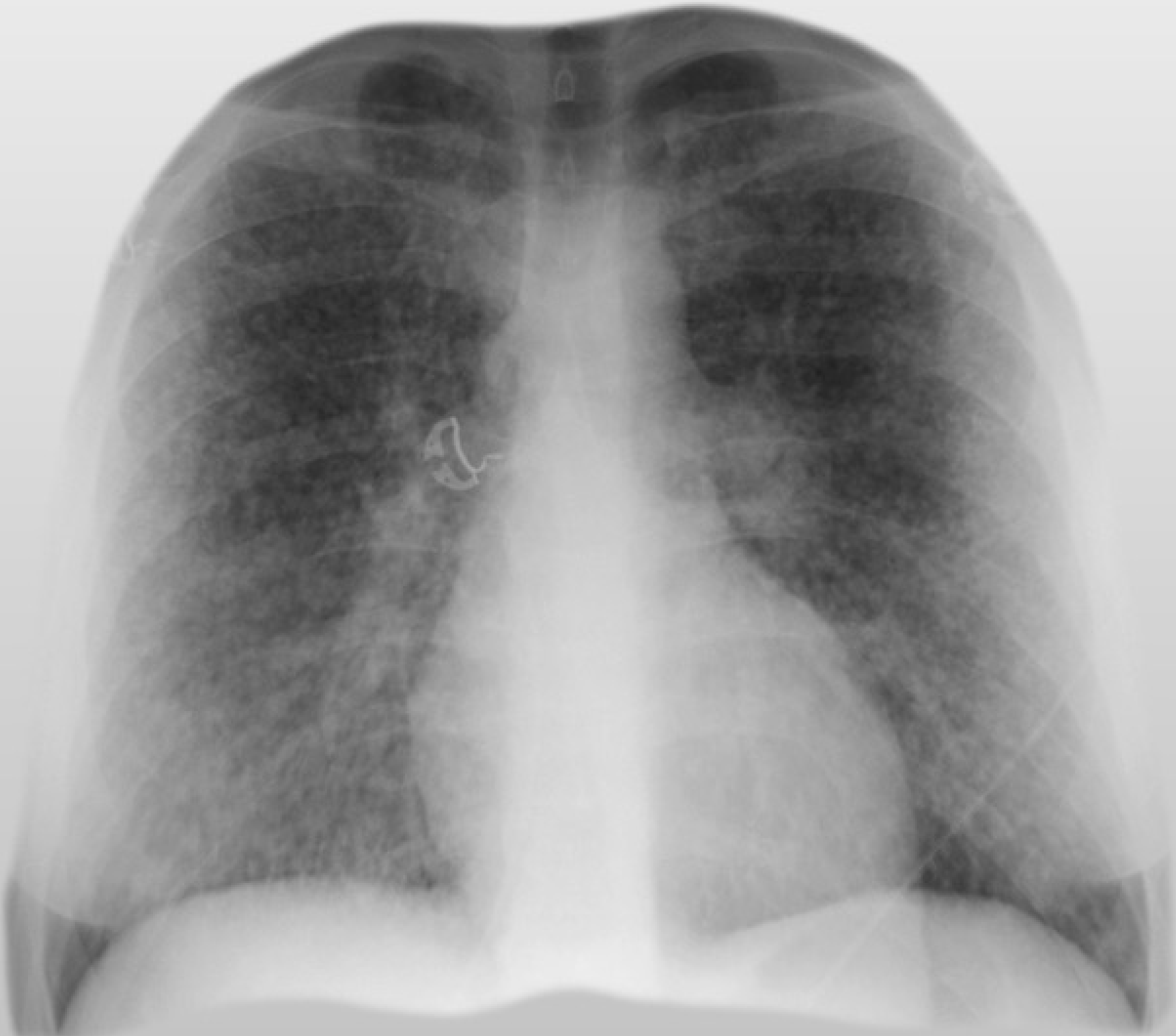
## Case 5

- 25-year-old male active duty military stationed in Iraq with rapidly progressive shortness of breath.

**Case 5**

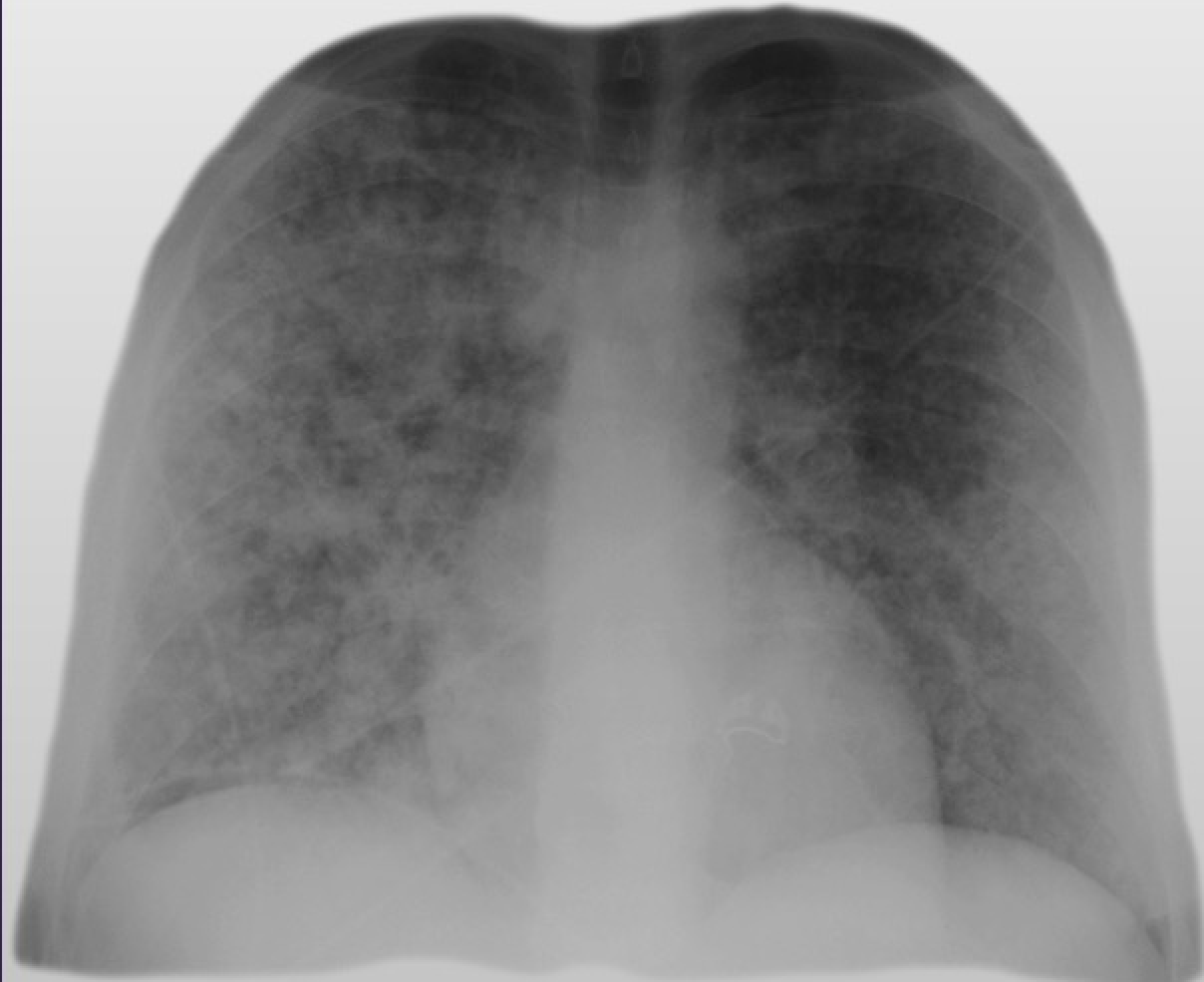


5/11/2017

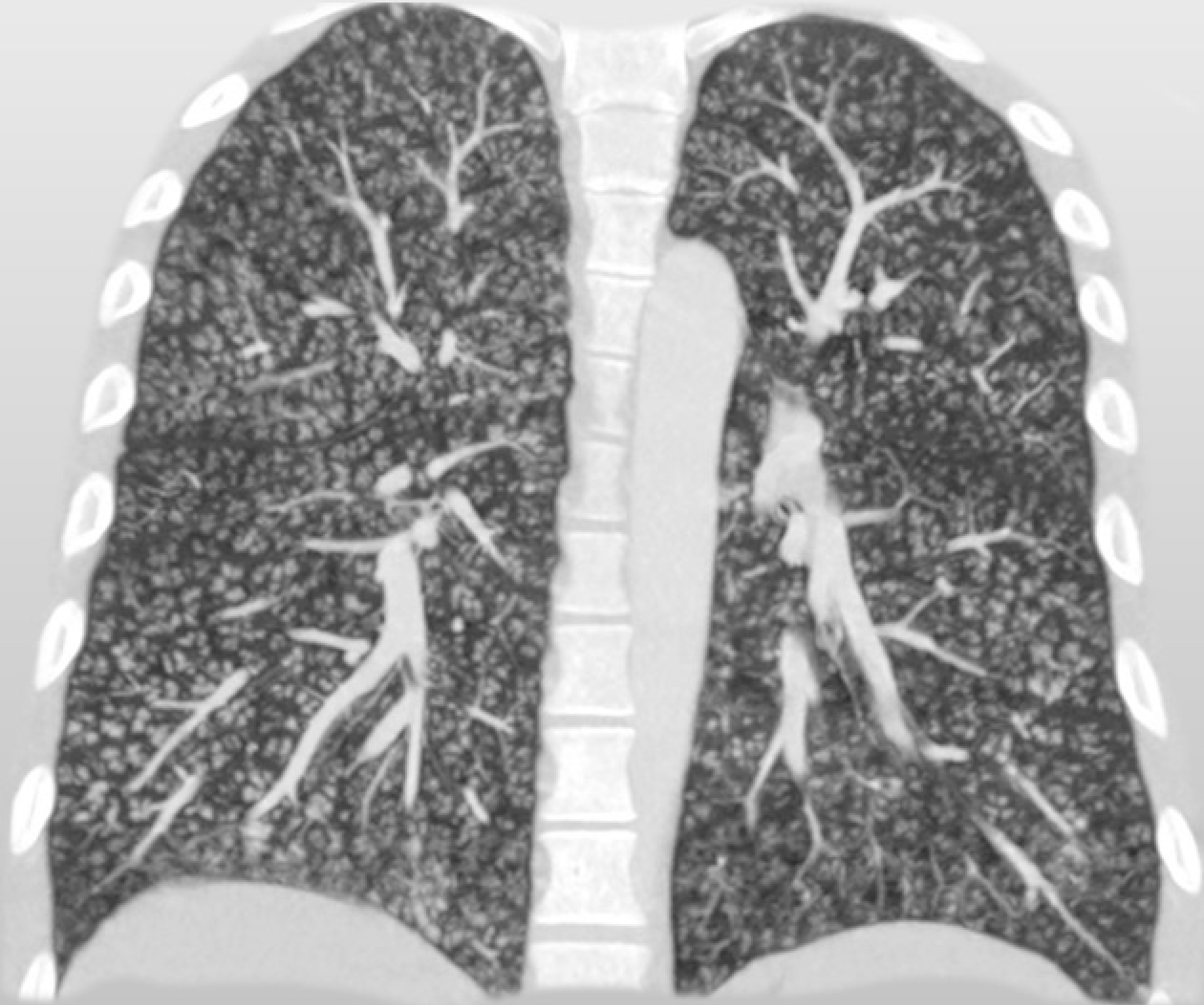

5/15/2017

# Case 5



5/11/2017

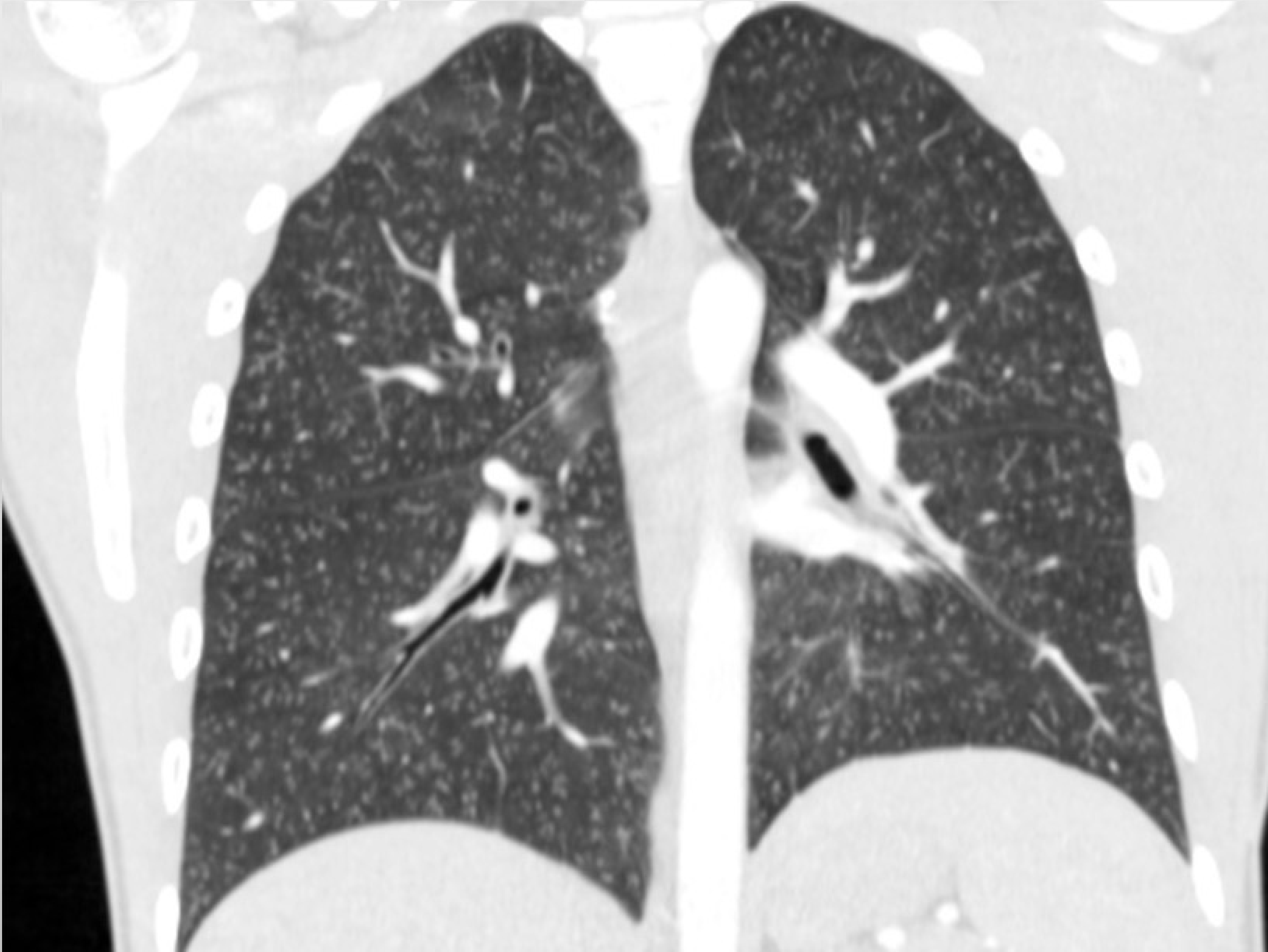


5/15/2017

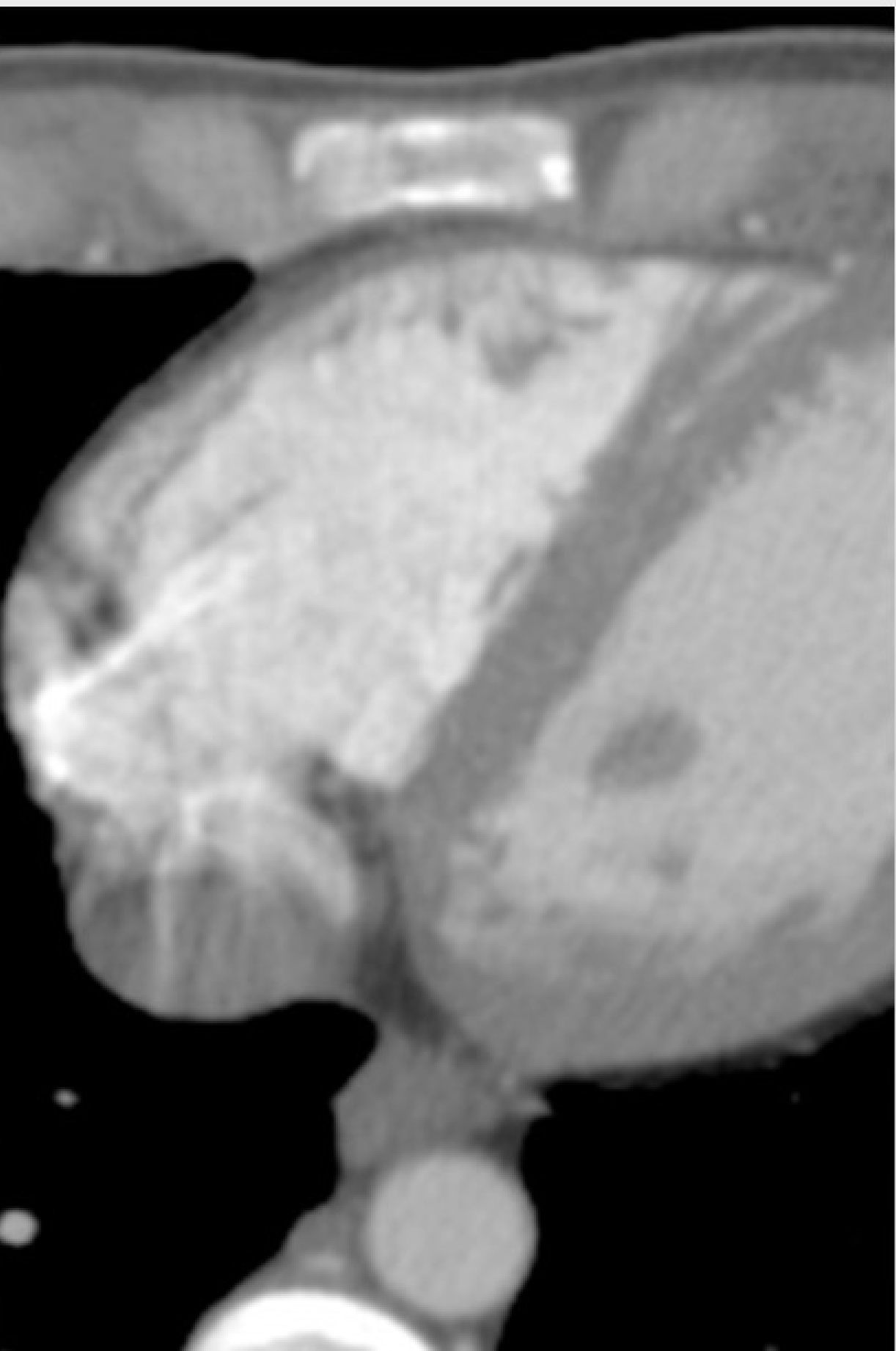
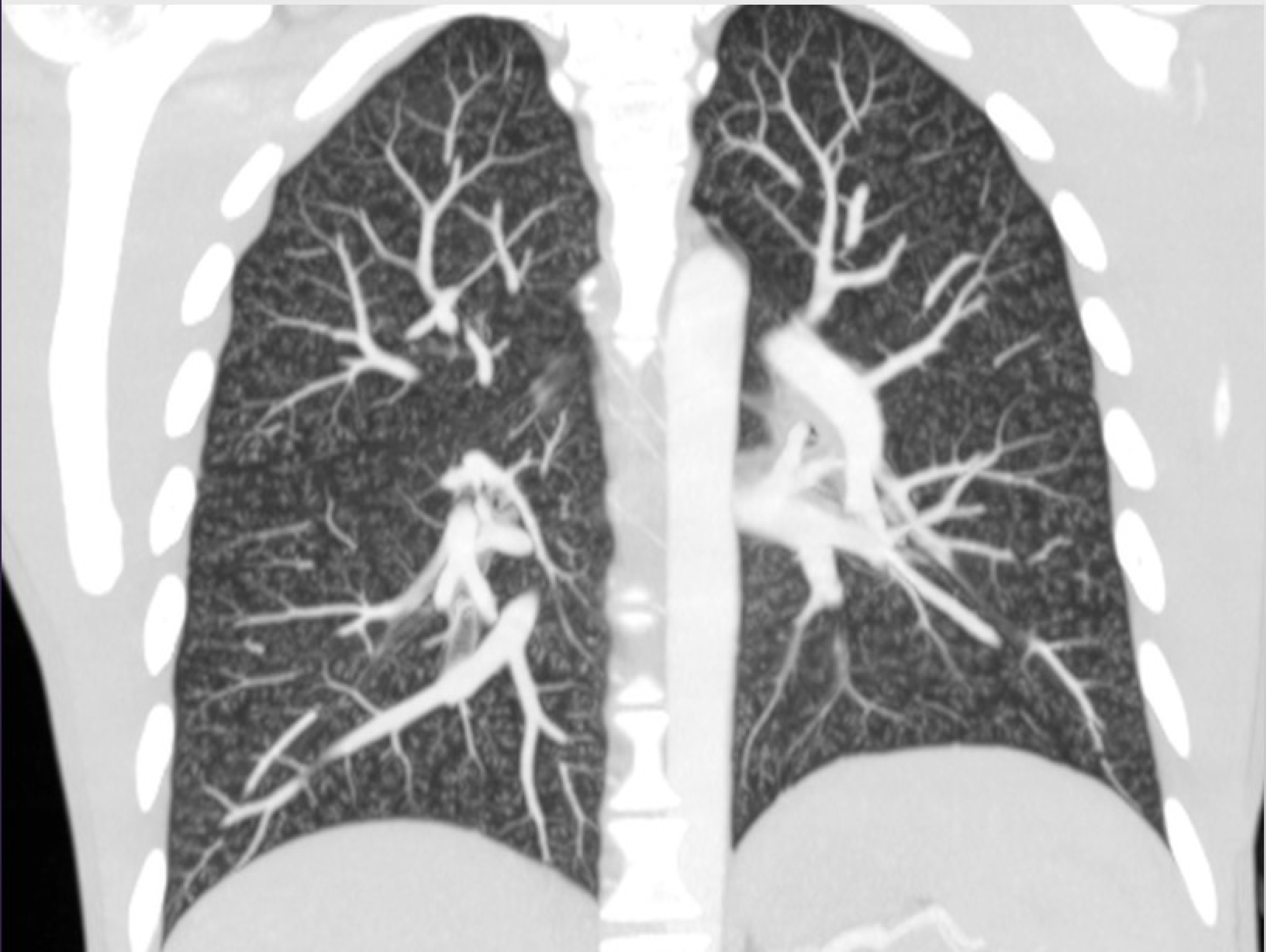
## Case 6

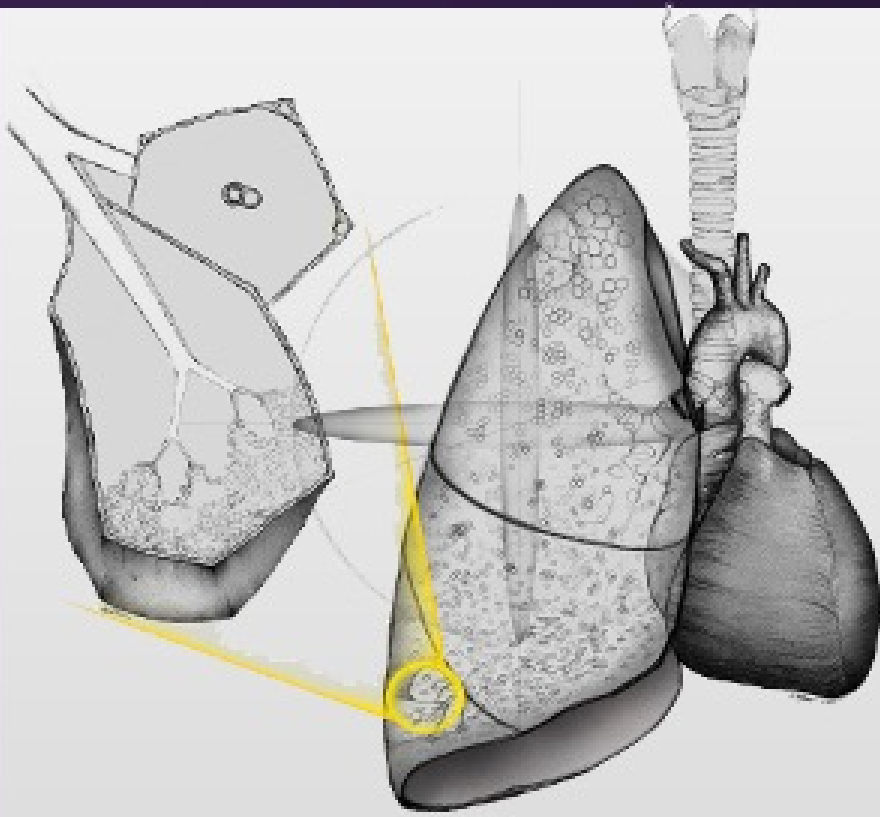
- 26-year-old male with methicillin-resistant *Staphylococcus aureus* (MRSA) pneumonia with a central line undergoing treatment at home. He presents with dyspnea and anxiety.

# Case 6



# Case 6





# Chest imaging correlates

Physiology, anatomy, histology, immunohistochemistry and genetics

Jeffrey R. Galvin, M.D

Teri J. Franks, M.D.

Nevins Todd, M.D.



UNIVERSITY of MARYLAND  
MEDICAL CENTER